

Original Research Article

Spectrum of Histopathological and Clinical Features in Psoriasis and Other Papulosquamous Skin Disorders

Sapana Bhadane¹, Sushant Bhadane²¹Assistant Professor, Department of Pathology, ²Associate Professor, Department of Radiology, SMBT Medical College, Dhamangaon Ghoti, Tal. Igatpuri, Dist Nasik, Maharashtra 422403, India.

Abstract

Background: Papulosquamous diseases characterized by scaling papules or plaques compose the largest heterogenous group of diseases. Psoriasis is the prototype of a group of cutaneous disorders that show Psoriasiform epidermal hyperplasia. **Aim:** To determine the histopathological & clinical pattern of Psoriasis and other papulosquamous disorders. **Materials and Methods:** Histopathological study of Papulo-squamous skin disorders was conducted at Department of Pathology. Sixty one cases attending dermatology OPD and fulfilling inclusion and exclusion criteria were selected for study. **Results:** Psoriasis occurred in all age groups except below 10 years but was commonly seen in young and middle age groups. Pityriasis rosea, Lichen nitidus, Prurigo simplex and inflammatory linear verrucous epidermal nevus were seen in children and young adults. High predominance was observed in males for all conditions. Fourty seven out of 61 cases showed clinic-pathological correlation which accounted for 77.05% of total cases. Twenty cases of Psoriasis were studied. Most common findings were parakeratosis, acanthosis, Munro microabscesses, hypogranulosis, spongiform pustules and dermal inflammation. **Conclusion:** Overlapping of both clinical pattern and distribution of papulosquamous skin disorders, which often made clinical diagnosis difficult. Proper clinical observation and histomorphological study will give conclusive diagnosis.

Keywords: Lichen planus; Scaly plaques; Eruptions; Pityriasis; Dermatitis.

Corresponding Author:

Sushant Bhadane, Associate Professor, Department of Radiology, SMBT Medical College, Dhamangaon Ghoti, Tal. Igatpuri, Dist Nasik, Maharashtra 422403, India.

E-mail: drsushbhadane@gmail.com

Received on 18.06.2019,

Accepted on 24.07.2019

How to cite this article:

Sapana Bhadane, Sushant Bhadane. Spectrum of Histopathological and Clinical Features in Psoriasis and Other Papulosquamous Skin Disorders. Indian J Pathol Res Pract. 2019;8(5):650-654.

Introduction

Papulosquamous diseases characterized by scaling papules or plaques compose the largest

heterogenous group of diseases observed by the dermatologist. Group of disorders characterized by scaling papules, confusion may happen in their diagnosis, therefore histopathology of lesions is

important for more conclusive diagnosis. This differentiation becomes important because the treatment and prognosis for each tends to be disease specific. Papulosquamous disorders includes skin diseases like Lichen planus, Psoriasis, Pityriasis rosea, Prurigo nodularis, Prurigo simplex, Lichen nitidus and Inflammatory Linear Verrucous Epidermal Nevus.¹

Psoriasis is the prototype of a group of cutaneous disorders (Psoriasiform dermatitides) that show psoriasiform epidermal hyperplasia, defined as regular elongation of the rete ridges with preservation of the rete ridge-dermal papillae pattern.² According to published reports, prevalence in different populations varies from 0% to 11.8%.^{3,4,5} In an India, overall incidence of Psoriasis is 1.02%.⁶

Papulo-squamous disorders are difficult to diagnose, because of the complexity in identification and may resemble closely with other disorders.⁷ The aim of the study was to determine the histopathological & clinical pattern of papulo-squamous disorders with special focus on Psoriasis.

Materials and Methods

A descriptive histopathological study of Papulo-squamous skin disorders was conducted from June 2010 to November 2012 at Department of Pathology in Dr, Vasantarao Pawar Medical College, Nashik. Institutional Ethics Committee (IEC) permission was taken before data collection. Sixty one cases of clinically diagnosed Papulo-squamous eruptions attending Department of Dermatology, Venerology and Leprosy of same institute in given time period were included. Cases attending dermatology OPD and fulfilling inclusion and exclusion criteria

were selected for study. Written informed consent was sought from each study participant. Patients having high bleeding time, clotting time, keloidal tendency and not willing to give consent were excluded. Cases with clinical features suggestive of papulosquamous skin disorders like Lichen planus, Psoriasis, Pityriasis rosea, Prurigo nodularis, Prurigo simplex and inflammatory linear verrucous epidermal nevus were included.

Standard operating protocols and procedures were fixed before start of study and followed throughout study. A brief clinical history and dermatological examination was carried out. Skin biopsies taken were fixed in 10% formalin and subjected for tissue processing. The processed tissue was embedded in paraffin to obtain 5 micron thin sections. The sections were stained with routine H & E stain, followed by microscopic examination. There H & E sections were studied and correlated with clinical features.

Data was entered in Microsoft Excel 2007 and analysed using SPSS V.16. To analyse data, descriptive statistics like frequency and proportions were used. Data summarised and presented with appropriate tables and figures.

Results

As shown in Table 1, Psoriasis occurred in all age groups except below 10 years but was commonly seen in young and middle age groups. Prurigo nodularis was seen in middle age groups. Pityriasis rosea, Lichen nitidus, Prurigo simplex and inflammatory linear verrucous epidermal nevus were seen in children and young adults. Lichen planus was seen in all age groups.

Table 1: Papulosquamous skin diseases- age wise distribution of cases.

Age group in years	Psoriasis	Lichen Planus	Prurigo Nodularis	Lichen Nitidus	Pityriasis Rosea	Prurigo Simplex	Inflammatory Linear Verrucous Epidermal Nevus
1 to 10	0	1	0	1	0	0	0
11 to 20	4	7	0	0	0	0	0
21 to 40	5	11	2	0	1	1	1
41 to 60	8	7	0	0	0	0	0
>60	3	9	0	0	0	0	0

Sixty one cases of papulosquamous disorders were included in present study. As highlighted in Table 2, high predominance was observed in males for all diseases. Lichen planus was the commonest

(57.37%) followed by Psoriasis (32.78%), Prurigo nodularis, Pityriasis rosea, Lichen nitidus, Prurigo simplex and inflammatory linear verrucous epidermal nevus.

Table 2: Papulosquamous skin diseases gender wise distribution of cases.

Disease	Female	Male	Total (%)
Psoriasis	5	15	20 (32.78)
Lichen Planus	14	21	35 (57.37)
Prurigo Nodularis	1	1	2 (3.27)
Pityriasis Rosea	0	1	1 (1.63)
Lichen Nitidus	0	1	1 (1.63)
Prurigo Simplex	0	1	1 (1.63)
Inflammatory Linear Verrucous Epidermal Nevus	0	1	1 (1.63)
Total	20	41	61 (100)

Outcome of histopathological and clinical diagnosis of Papulosquamous skin disorders is shown in Table 3. Fourteen out of 61 cases had 2 or more clinical differential diagnosis. Histologically we were able to diagnose these lesions. This accounted for 22.95% of total cases which need histopathological study to get a more definitive diagnosis. Fourty seven out of 61 cases showed clinic-pathological correlation which accounted for 77.05% of total cases. Lichen nitidus presented with

papule and flat topped plaque. Histologically it had circumscribed chronic inflammatory infiltrate. Prurigo simplex had acanthosis and parakeratosis. Inflammatory Linear Verrucous Epidermal Nevus had focal parakeratosis and acanthosis. Prurigo nodularis had hyperkeratosis and papulomatosis. Pityriasis rosea presented with scaly plaque, patch and macule. Histologically common features were parakeratosis and upper malphigian spongiosis.

Table 3: Outcome of histopathological and clinical diagnosis of Papulosquamous skin disorders.

Histopathological diagnosis	Clinical diagnosis*								
	LP	PSO	PR	PN	PR	LN	PS	TVC	2 or more DD
Lichen Planus	29	1	0	1	0	0	0	1	3
Psoriasis	2	14	1	0	0	0	0	0	3
Prurigo Nodularis	2	0	0	0	0	0	0	0	0
Pityriasis Rosea	0	0	1	0	0	0	0	0	0
Lichen Nitidus	0	0	0	0	0	1	0	0	0
Prurigo Simplex	0	0	0	0	1	0	0	0	0
Inflammatory Linear Verrucous Epidermal Nevus (ILVEN)	0	0	0	0	0	0	0	0	1

*LP-Lichen planus, Pso-Psoriasis, PN-Prurigo nodularis, PR-Pityriasis rosea, LN-Lichen nitidus, PS-Prurigo simplex, TVC-ILVEN, DD-Differential diagnosis

Figure 1 and Table 4 depict clinical presentations and histopathological changes in Psoriasis. Twenty cases of Psoriasis were studied. Most common findings were parakeratosis, acanthosis, Munro microabscesses, hypogranulosis, spongiform pustules and dermal inflammation. Suprapapillary

thinning and vascular changes were seen in few cases. Out of 20 cases of histopathologically diagnosed Psoriasis, 2 cases were clinically diagnosed as Eczema, Mycosis fungoides, Pemphigus vulgaris and Bullous pemphigoid. In 2 cases, Psoriasis was in differential diagnosis with eczema.

Table 4: Histological changes observed in Psoriasis.

Histopathological changes	No. of cases	%	
Epidermal changes	Hyperkeratosis	5	25
	Parakeratosis	15	75
	Acanthosis	18	90
	Suprapapillary thinning	4	20
	Spongiform pustule	11	55
	Munro microabscesses	15	75
	Hypogranulosis	10	50

Histopathological changes		No. of cases	%
Dermal changes	Pappillary edema	3	15
	Vascular changes	2	10
	Dermal inflammation	18	90

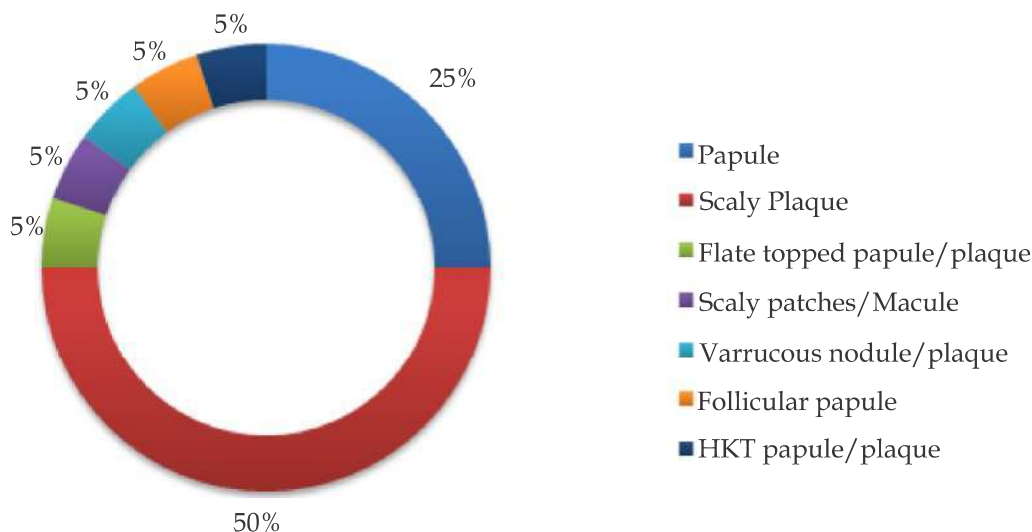


Fig. 1: Clinical pattern of histopathologically diagnosed Psoriasis.

Discussion

Papulosquamous skin disorders have many differential clinical diagnosis and histological variation. In present study, Psoriasis was seen commonly in 41 to 50 years of age group. Alexander *et al.*⁸ reported maximum incidence of Psoriasis in the age group of 40 to 50 years. Thippeswamy⁹ reported it to be common in middle age group. Mani¹⁰ reported the commonest age group as 41 to 50 years. In present study, Male to female ratio in Psoriasis cases was 3:1. Mani¹⁰ reported female preponderance. Thippeswamy⁹, Alexander⁸ and Yang *et al.*¹¹ showed M:F ratio more than 3. Seema *et al.*¹² reported 2.5:1 (M:F) ratio.

Out of 35 cases, 29 diagnosed as Lichen planus were confirmed histologically. Lichen planus must be differentiated from other papulosquamous disorders such as Psoriasis and others 22. Hence confirmation with skin biopsy is always warranted¹³ to exclude few other papulosquamous disorders. Out of 20 cases of clinically diagnosed Psoriasis, 4 cases were histologically different diseases because the clinical presentation of Psoriasis was varied and mimicked other papulosquamous diseases encountered in present study.¹³ Hence, many times the definitive diagnosis depends on histologic diagnosis.

In present study, among 20 cases of Psoriasis, 14 cases had clinical differential diagnosis of Psoriasis. Six cases had differential diagnosis as Lichen Planus, mucosis fungoides, bullous pemphigoid, pemphigus foliaceus, eczema and pityriasis rosea. Mani¹⁰ had studied 23 cases of Psoriasis, of which 22 cases had clinically differential diagnosis of Psoriasis. One case had no clinical suspicion of Psoriasis, which was diagnosed as Leprosy. Psoriasis most commonly had a differential diagnosis of contact dermatitis. Lichen planus and pityriasis rosea can be confused with Psoriasis clinically.¹⁴

Conclusion

There was overlap of both clinical pattern and distribution of papulosquamous skin disorders, which often made clinical diagnosis difficult. Some of the histological features overlapped in lesions like Pityriasis rosea, prurigo nodularis and Prurigo simplex.

However some of the histologic features were specific and characteristics to each entity. Hence, Combination of proper clinical observation and histomorphological study will give conclusive diagnosis.

References

1. Younas M and Haque A. Spectrum of Histopathological Features in Non Infectious Erythematous and Papulosquamous Diseases. *International Journal of Pathology*; 2004;2(1):24-30.
2. Murphy M, Kerr P, Jane M. Grant-Kels. The histopathologic spectrum of psoriasis. *Clinics in Dermatology*. 2007 Nov-Dec;25(6):524-8.
3. D' Costa G, Bharambe BM. Spectrum of non-infectious erythematous, papular and squamous lesions of the skin. *Indian J Dermatol*. 2010;55(3):225-228.
4. Gaikwad R, Deshpande S, Raje S. Evaluation of functional impairment in psoriasis. *Indian J Dermatol Venereol Leprol*. 2006;72:37-40.
5. Kumar B, Jain R, Sandhu K. Epidemiology of childhood psoriasis: a study of 419 patients from northern India. *Int J Dermatol*. 2004;43:654-8.
6. Dogra S, Yadav S. Psoriasis in India: Prevalence and pattern. *Indian J Dermatol Venereol Leprol*. 2010;76:595-601.
7. Norman RA, Blanco PM. Papulosquamous diseases in the elderly. *Dermatol Ther*. 2003;16(3):231-242.
8. Alexander E, Pinto J, Pai GS, *et al*. Disease concomitance in Psoriasis: A clinical study of 61 cases. *Indian J Dermatol Venereol Leprol* 2001;67:66-8.
9. Thippeswamy MTR. Histomorphologic study of papulosquamous disorders of skin. *Ind J Dermatol* 2000;3:104-7.
10. Mani A. Histological spectrum of papulosquamous lesions of skin, encountered at MSRMC from January 2003 to December 2005. *Ind J Dermatol*. 2006;4:152-6.
11. Yang Y, Koh D, Khoo L. The Psoriasis disability index in Chinese patients: Contribution of clinical and psychological variables. *Int J Dermatol*. 2005;44:925-9.
12. Seema BN. Histopathological study of papulosquamous disorders of skin. *Mysore J Dermatol*. 2010;4:135-8.
13. Wu H, Harnist TJ, Branding-Bennett HA. Non-infectious vesiculobullous and vesiculopustular diseases. In Elder DE editor; *Lever's histopathology of the skin*. 10th edition, Wolters Kluwer (India) Pvt. Ltd., New Delhi, 2010:235-278.
14. Chaudhary R G *et al*. Study of Clinico-histopathological Correlation of Papulosquamous Disorders at Tertiary Care Hospital. *Sch. J. App. Med. Sci*. 2015; 3(3B):1154-58.

